

## VARIOUS PRESENTATIONS OF HYDATID DISEASE AND THEIR MANAGEMENT: A STUDY AT RIMS, KADAPA, A. P.

T. Giridhar<sup>1</sup>, P. Suresh Babu<sup>2</sup>

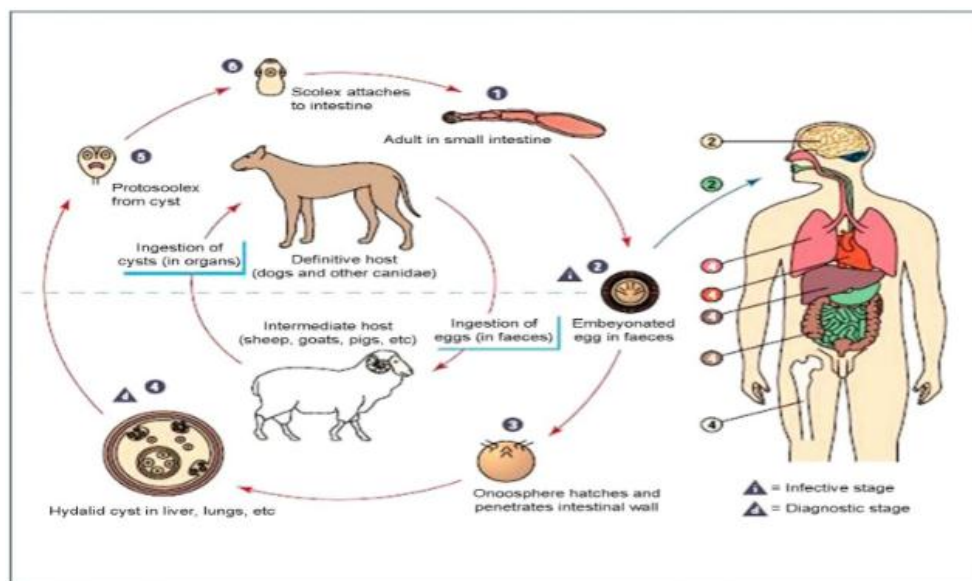
### HOW TO CITE THIS ARTICLE:

T. Giridhar, P. Suresh Babu. "Various Presentations of Hydatid Disease and their Management: A Study at RIMS, Kadapa, A. P". Journal of Evolution of Medical and Dental Sciences 2015; Vol. 4, Issue 49, June 18; Page: 8483-8488, DOI: 10.14260/jemds/2015/1230

**ABSTRACT:** Hydatid disease most often involves the liver and lung. Actually it can involve any part of the body but primary extra hepaticopulmonary hydatid cyst are rare and their presentation is sporadic. **MATERIALS AND METHODS:** A retrospective study of 21 cases of hydatid disease reported at RIMS, Kadapa, A. P. from 2012 involving liver, spleen, peritoneal cavity, breast and soft tissues. **RESULTS:** All the cases are successfully operated without any complications-liver (12), spleen (3), peritoneal cavity (2), omentum (3), breast (1), soft tissue at axilla (1). **CONCLUSION:** Atypical presentation of hydatid cyst is rare and more common in endemic areas like India. Even though the living conditions has improved, it is still prevalent in the society. It should be a differential diagnosis for any cystic swelling in a patient from endemic area.

**KEYWORDS:** Atypical location, Hydatid cyst, Echinococcosis.

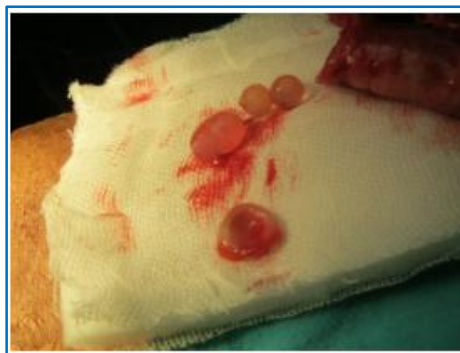**INTRODUCTION:** Hydatid disease is still a public health problem with a different geographical distribution in the world.<sup>(1)</sup> The disease is caused by infection with larval stage of genus *Echinococcus granulosus* and *E. multilocularis*.<sup>(2)</sup> *Echinococcus granulosus* (Dwarf tapeworm) is 5 mm long. Dogs and fox are the definite hosts whereas sheep, swine, cattle, zebra are the intermediate hosts. Man is accidental intermediate host with dead end. Once within the man the ingested eggs hatch in the duodenum to release oncospheres that penetrate the mucosa in the small intestine and enter the portal circulation.



**Fig. 1: Life cycle of echinococcus granulosus (source: Center for disease control and prevention)**

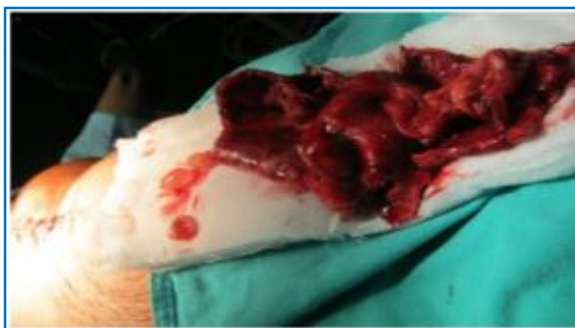## ORIGINAL ARTICLE

Liver is the first filter and most common site for hydatid disease.<sup>(3)</sup> Some may reach the lung, second filter and into systemic circulation causing hydatid disease in peritoneal cavity, spleen, breast, soft tissues and other parts.<sup>(4)</sup> Other mode of dissemination is through lymphatics. Secondary bacterial infection can lead to abscess formation. Liver hydatid can get infected by ascending infection via bile duct or portal vein. Rarely can it regress spontaneously. In the natural course of healing calcification can occur. Our aim is to review various atypical presentations of hydatid disease and their management in our Institute, RIMS, Kadapa, A. P.

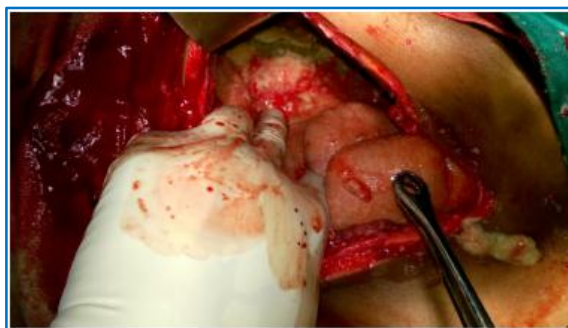

**Fig. 2: Hydatid cyst**

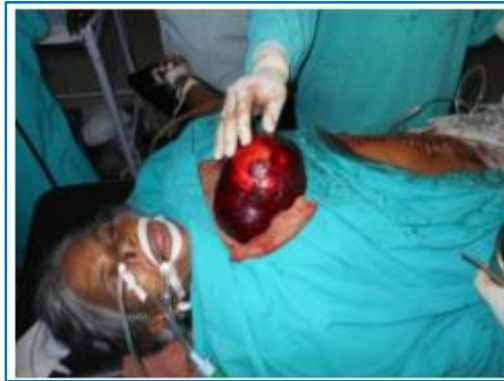**MATERIALS AND METHODS:** A retrospective study was done on 21 patients of hydatid disease who were managed successfully at RIMS kadapa from 2012. Of these patients 12 were males and 09 were females. Patients' age ranged from 32 to 65 years. Liver was involved in 12 cases, spleen in 3 cases. Omentum in 03 cases, peritoneal cavity in 02 cases, breast in 01 case and soft tissue in axilla was involved in 01 case. Diagnosis depends on history, clinical examination, biochemical investigations, Serology and pathological diagnosis. Radiological investigations involve ultra sound, CT, and MRI. Sonography is the most sensitive technique for detection of membranous septae and hydatid sand within the cyst. CT is best to show the calcification, cyst infection and peritoneal seedings. MRI shows low signal intensity rim of the hydatid cyst<sup>(5)</sup>. FNAC is also a useful diagnostic method as it does not cause any complication. It has been reported to be useful sometimes when serology is negative<sup>(6)</sup>. Diagnosis is difficult when disease is present at unusual location (atypical site)<sup>(7)</sup>. Surgery with complete removal of cyst is the main stay of treatment with high success rate. Chemotherapy with albendazole has also been used with some success to sterilize the cyst. Symptoms of the disease vary according to the localization of the cyst (Table 1).



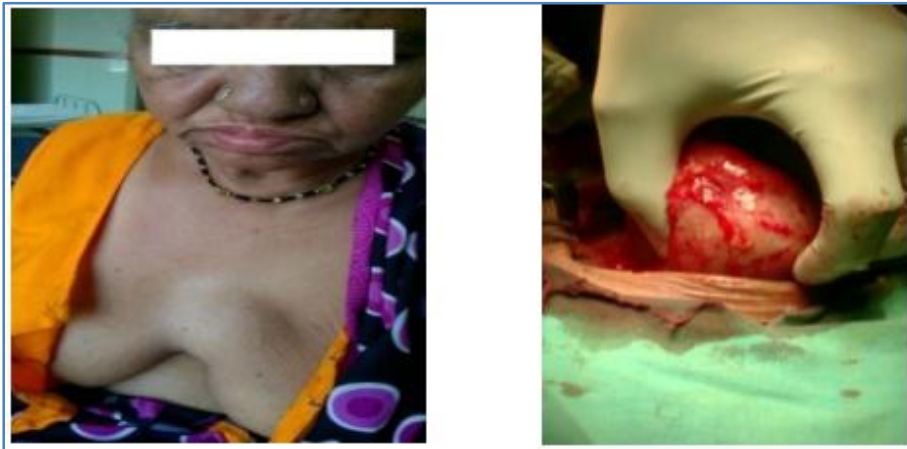**Fig. 3: Cystectomy in Hydatid liver**



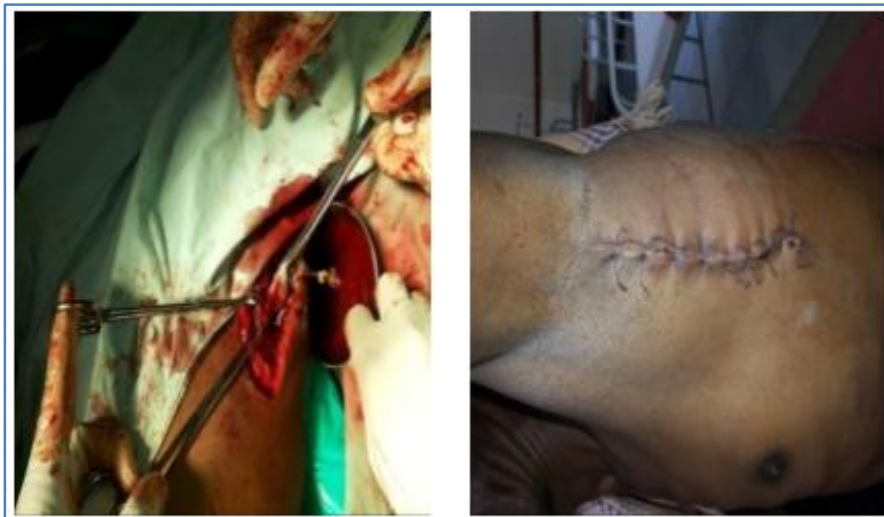**Fig. 4: Hydatid cyst in omentum**



**Fig. 5: Hydatid spleen in a female aged 64 years**



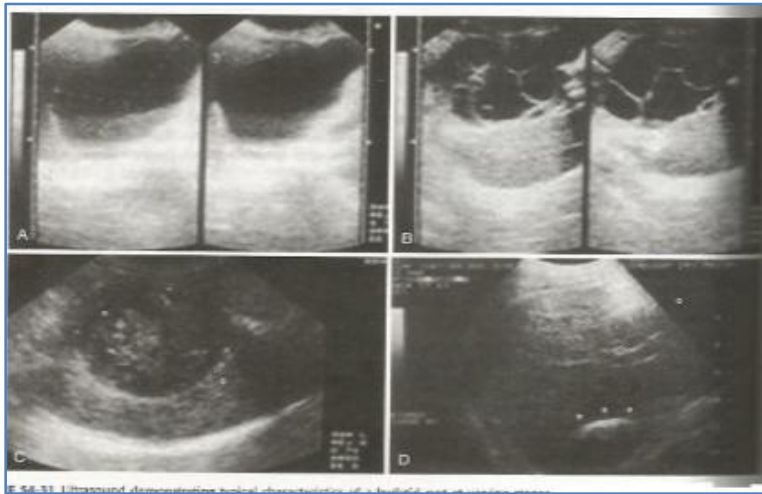
**Fig. 6: Hydatid breast - Cystectomy**



**Fig. 7: Hydatid cyst in axila**

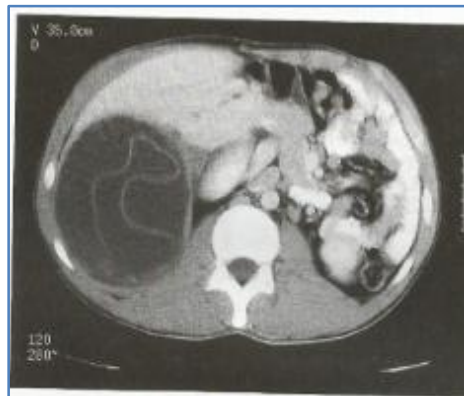## ORIGINAL ARTICLE

**Figure 8A:** Ultra sound images of various stages of Hydatid cyst A. Simple Hydatid cyst B. Daughter cysts Hydatid Cyst C. Cyst with amorphous mass D. Calcified cyst.



**Fig. 8A**

**Figure 8B:** C.T. Scan Abdomen–Non calcified with floating layers.



**Fig. 8B**

Cyst Location	No. of patients	Symptoms	Surgical treatment
Liver	12	Right upper quadrant pain, abdominal lump, jaundice	Cystectomy
Spleen	03	left upper quadrant pain, abdominal lump	Splenectomy
Peritoneum	02	Asymptomatic, abdominal pain, abdominal lump	cystectomy
Omentum	02	Abdominal pain, abdominal lump	Omentectomy
Subcutaneous	01	Palpable lump, pain	Cystectomy
Breast	01	Breast lump, pain	Cystectomy

**Table 1: Localization of hydatid cysts**

## ORIGINAL ARTICLE

---

**RESULTS:** Hydatid disease involving atypical location was seen in total of 09 patients. These include spleen, peritoneum, omentum, axila, breast. Surgical treatment include complete cyst excision (cystopericystectomy) in most of the patients. Splenectomy was performed whenever spleen was involved. Preoperatively these patients were immunized against capsulated bacteria. All the patients received postoperatively albendazole 10mg /bodywt. Post op hospital stay was from 04 to 09 days. All the patients were successfully operated. Morbidity was nil. No recurrence was noted in follow up.

**DISCUSSION:** Human Echinococcus is a zoonotic infection caused by tape worm of genus Echinococcus granulosus. Incidence in endemic area range from 1 to 220 per 100,000 inhabitants.<sup>(8)</sup> Infestation of hydatid disease in human most commonly occurs in liver (55-70%), lung (18-35%). The disease can occur anywhere (3%).<sup>(9)</sup> Hepatic hydatid cyst causes highly variable symptoms and signs and can be found incidentally in asymptomatic patients. The symptoms and signs may be caused by toxic reaction to the parasite or by local mechanical effect depending upon the location and nature of the cyst and presence of complication.<sup>(10)</sup> Early diagnosis and proper treatment will help to reduce the complication rate and prevent recurrence. Involvement of spleen is rare and is 3<sup>rd</sup> most common site after liver and lung. The incidence of splenic involvement range from 0.9% to 8%.<sup>(11)</sup> It develops secondary to systemic dissemination or intraperitoneal spread from ruptured liver hydatid cyst. The differential diagnosis include epidermoid cyst, pseudocyst, abscess, hematoma, and neoplasm.<sup>(12)</sup> Intra peritoneal hydatid cyst accounts for 13%. It develops secondary to spontaneous or iatrogenic rupture of hepatic, splenic or mesenteris cyst and can localize anywhere in the peritoneum. Omentum is the one of the rare site of isolated hydatid disease.<sup>(13)</sup> Total excision of the cyst without rupture is recommended in omental hydatid cyst. Primary sub cutaneous hydatid disease is very rare and the incidence rate is unknown. Subcutaneous hydatid disease may be primary or secondary. The mechanism of spread is unclear. Direct spread from the adjacent site may be the mechanism of infection.<sup>(14)</sup> The treatment is always total surgical excision.

**CONCLUSION:** Hydatid disease is still prevalent disease in endemic areas. Liver and lung are usual sites, but its occurrence at other sites cannot be ruled out. These variations make it difficult to diagnose. It should be always a differential diagnosis of a cystic swelling in a patient from endemic region. Prompt diagnosis and surgical management is required for successful outcome and to prevent recurrence. In our study all the Hydatid cysts encountered in various sites successfully operated without any recurrence.

### REFERENCES:

1. Dziri C: Hydatid disease: Continuing Serious Public Health Problem. World J Surgery. 2001; 25: 1-3.
2. Yildirim Merkan N, Vardar E. Ann Trop Med Parasitol 2006 Mar; 100: 137-42.
3. Prousaladis J, Tzardioglou K, Sgouradis L, Katsohis C, Uncommon Sites of Hydatid Disease. World J Surgery 1998; 22; 17-22.
4. Engin G, Acunas B, Rozanes I, Hydatid Disease with Unusual Localization. Eur Radiol 2000; 10: 1904-1912.
5. Gharbi Ha, Hassine W, Brauner Mw, Dupuch K. Ultrasound Examination of Hydatid Liver. Radiology 1981; 139: 459-463.

## ORIGINAL ARTICLE

6. Bmarwah S, Subramanian P, Rattan Kn, Karwasra Rk. Infected Primary Intramuscular Echinococcosis of Thigh. Indian J Paed 2005; 72: 799-800.
7. Echenique Elizondo Mm, Amondarain Arratibel Ja. Muscular Hydatid Disease. J Am Coll Surg 2003; 197: 162.
8. Taori K, Sanyal R, Rathod J, Et Al. Ct Appearance Of Hydatid Disease At Various Locations. Australas Radiol 2006 Aug; 50: 298-305.
9. Safioleas Mc, Misiakos Ep, Kouvaraki M, Stamatakos Mk, Manti Cp. Hydatid Disease Of Liver A Continuing Surgical Problem. Arch Surg 2006; 141: 1101-1108.
10. Sayek S, Tirnaksi Zb, Dogan R, Cystic Hydatid Disease: Current Trends in Diagnosis and Management. Surgery Today; 2004; 34: 987-96.
11. Polat P, Kantarci M, Alper F, Suma S, Koruyucu Mb, Okur A. Hydatid Disease From Head To Toe. Radiographics 2003; 23: 475-494.
12. Durgun V, Kapan S, Kapanm, Karabicak I, Aydogan F, Goksoy E; Primary Splenic Hydatidosis. Dig Surg 2003; 20: '38- 41.
13. Karavias Dd, Vagianos Ce, Kakkos Sk, Panagopoulos Cm, Androulakis Ja. Peritoneal Echinococcosis. World J Surg 1996; 20; 337-40.
14. Safioleas M, Nikiteas N, Stamatakos M, Et Al. Echinococcal Cyst of the Subcutaneous Tissue: A Rare Case Report. Parasitol Int 2008; 57: 236-8.

### AUTHORS:

1. T. Giridhar
2. P. Suresh Babu

### PARTICULARS OF CONTRIBUTORS:

1. Associate Professor, Department of General Surgery, RIMS, Kadapa, Andhra Pradesh, India.
2. Post Graduate, Department of General Surgery, RIMS, Kadapa, Andhra Pradesh, India.

### FINANCIAL OR OTHER

**COMPETING INTERESTS:** None

### NAME ADDRESS EMAIL ID OF THE CORRESPONDING AUTHOR:

Dr. T. Giridhar,  
Associate Professor,  
RIMS, Kadapa,  
Andhra Pradesh, India.  
E-mail: tirupathigiridhar@gmail.com

Date of Submission: 27/05/2015.  
Date of Peer Review: 28/05/2015.  
Date of Acceptance: 11/06/2015.  
Date of Publishing: 16/06/2015.